

Case Report

Patent Vitellointestinal Duct along with Patent Urachus: A Rare Incidence

Muhammed Foysol Ahmed¹, Mohammed Abdul Momin², Md Abdullah Al Mashuque³

¹Assistant Professor, Department of Paediatric Surgery, Jalalabad Ragib-Rabeya Medical College, Sylhet.

²Associate Professor, Department of Paediatric Surgery, Jalalabad Ragib-Rabeya Medical College, Sylhet.

³IMO, Department of Paediatric Surgery, Jalalabad Ragib-Rabeya Medical College Hospital, Sylhet.

ABSTRACT

A rare case of patent vitellointestinal duct along with patent urachus in an 8 months old male baby is reported here, who presented with umbilical discharge and swelling of the umbilicus since the separation of the umbilical cord. Our initial diagnosis was umbilical adenoma. On exploration, the umbilicus was connected to the ileum and the apex of the urinary bladder through two communicating channels. The urachus was completely excised after ligation, the patent vitellointestinal duct was resected and the ileum anastomosed.

Keywords: Patent urachus, Patent vitellointestinal duct.

[Jalalabad Med J 22; 19 (1): 31-34]

INTRODUCTION

The umbilical cord is the main portal for entry and exit of blood from the placenta to the foetus during intrauterine life. In addition to the paired umbilical arteries and umbilical vein, the umbilical cord also contains the vitellointestinal or omphalomesenteric duct and the urachus (Figure-1). Usually, the vitellointestinal duct obliterates by the 5th to 9th week of gestation, and the urachus obliterates to become the median umbilical fold by the 4th to 5th month of intrauterine life. Failure to obliterate these structures gives rise to various congenital umbilical disorders which manifest as umbilical discharge, swelling, mass, and abdominal pain^{1,2}.

The urachus is an embryonic remnant resulting from involution of the allantois, a canal that drains the urinary bladder (Cloaca) of the foetus, while the vitellointestinal duct is a communication between the

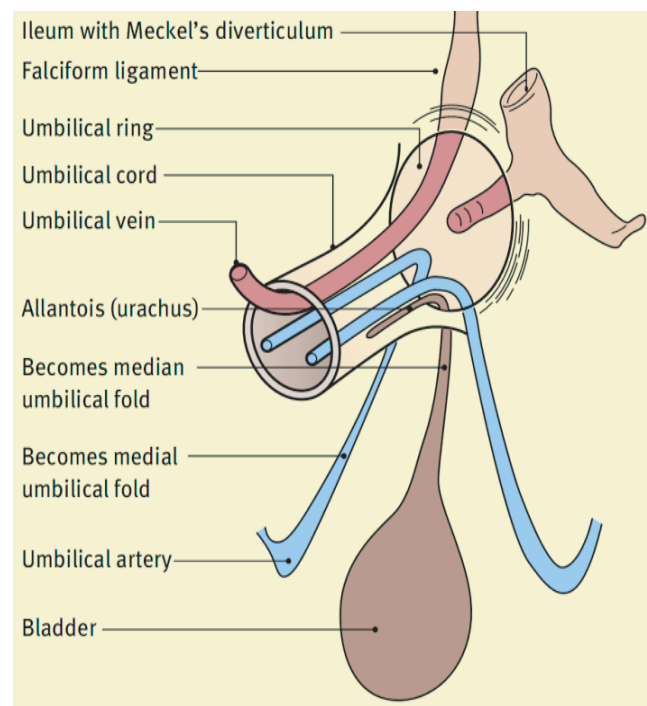


Figure-1: Structures at the umbilical ring and in the umbilical cord³.

Address of Correspondence: Dr. Muhammed Foysol Ahmed, Assistant Professor, Department of Paediatric surgery, Jalalabad Ragib-Rabeya Medical College, Sylhet, Mobile: 01712233401, E-mail: drfoysol77@gmail.com

midgut and the yolk sac. A patent urachus (PU) is a rare occurrence, with an estimated incidence of 1-2 per 100000, while patent vitellointestinal duct (PVID) has an incidence varying from 1 in 5000 to 8000 live births⁴. A patent urachus being associated with a patent vitellointestinal duct is very rare. We are presenting a case of patent urachus along with a patent vitellointestinal duct.

CASE REPORT

An 8 months old male baby presented with umbilical discharge and a swelling on the umbilicus since the separation of the umbilical cord. He was born at home at term. Mother's antenatal period was uneventful but not monitored sonographically. The base of the umbilical cord was slightly swollen and separated on the 4th day. After separation of the cord, parents noticed a yellowish discharge from the umbilicus. The discharge was foul-smelling and small in amount. Occasionally, clear, watery fluids came out through the umbilicus when the baby cried excessively. The patient passed urine and stools normally. The baby was seen by local physicians but the discharge did not stop. A few days later, they noticed a small pinkish mass on the umbilicus along with discharge. The mass was enlarging gradually. Chemical cauterization of the mass was done by a local physician. Following cauterization, the mass was reduced initially but, later on, recurred in its enlarged size. On examination, the umbilicus was inverted. A pinkish mass arising from the umbilicus, measuring about 1.25x1 cm in size, the surface smooth with slight discharge and peri-umbilical excoriation. Other abdominal findings revealed that everything was normal (Figure-2).

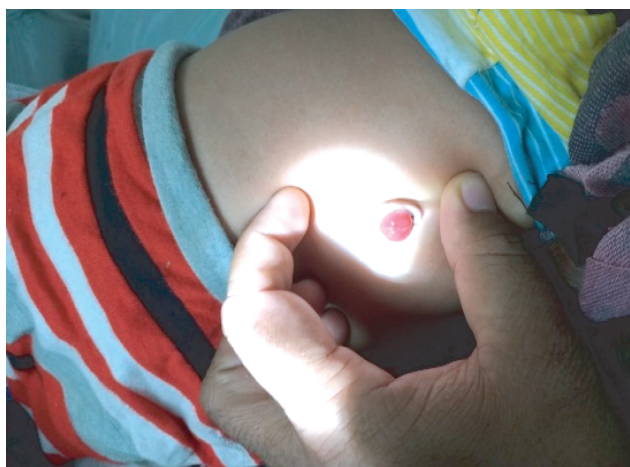

Figure-2: pre-operative picture showing adenoma arises from umbilicus.

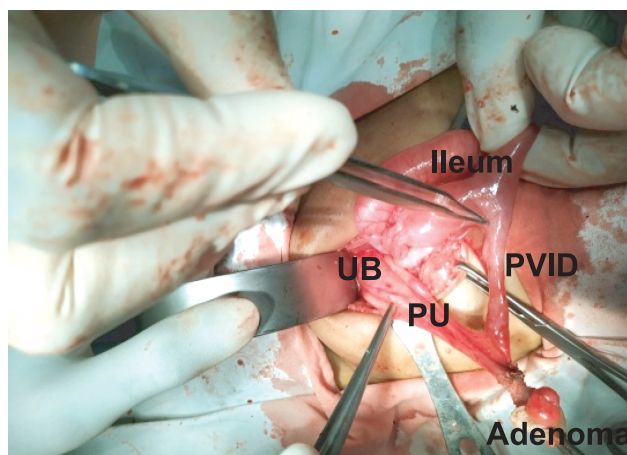


Figure-3: Per-operative picture showing patent urachus (PU), patent vitellointestinal duct PVID and excised umbilical adenoma, ileum and urinary bladder (UB).

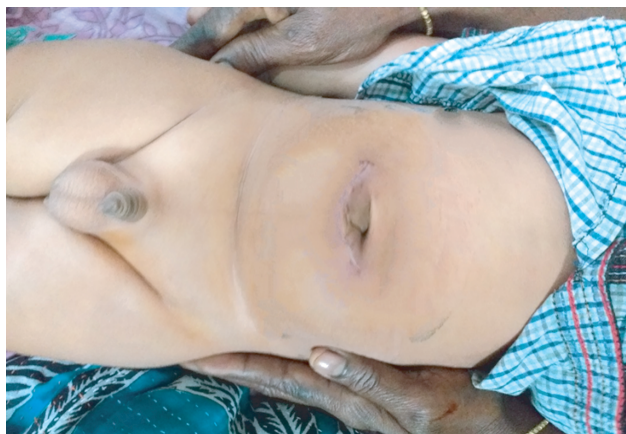

Figure-4: Picture during discharge showing healthy looking umbilicus and incision mark.

Ultrasonography also revealed normal findings. Our clinical diagnosis was umbilical adenoma, and we decided to do an exploratory laparotomy. During exploration, two communicating tracts connecting the umbilicus to the apex of the urinary bladder and the umbilicus to the ileum were seen. Both tracts were meticulously separated, ligated and excised. This included wedge excision of the vitellointestinal duct (VID) at the base, followed by transverse anastomosis of the gut and excision of the urachus near the urinary bladder following ligation. An umbilical adenoma was excised along with the common tract (Figure-3). Umbilicoplasty was done and the specimen was sent for histopathology. The postoperative period was uneventful and the patient was doing well (Figure-4).

DISCUSSION

Umbilical discharge is common in children. It is a symptom of varied pathology. Some congenital anomalies such as umbilical adenoma, patent VID, patent urachus, and some acquired diseases such as omphalitis and umbilical granuloma are key concerns for paediatric surgeons and paediatricians. Some need operative treatment, while others can be managed non-surgically.

Vitellointestinal duct anomalies are due to failure or incomplete obliteration of the vitellointestinal duct⁴. The most frequent VID malformation is Meckel's diverticulum, and the rarest is complete patency of the duct. The incidence of Meckel's diverticulum is 2-3% of the population, but mostly non-symptomatic. About 4% of children with a Meckel's diverticulum develop symptoms and more than 60% are younger than 2 years of age⁵.

A patent urachus is a communication from the umbilicus to the bladder. It is due to failure of complete obliteration of the urachus and presents as leaking of urine through the umbilicus. Lower urinary tract obstruction may also be a contributing factor⁴.

A patent vitellointestinal duct (PVID) becomes symptomatic early in life as a feculent or serous discharge through the umbilicus. Without treatment, the disease can last into adulthood^{6,7,8}. Diagnosis of a symptomatic vitellointestinal duct malformation depends on anatomic configuration, signs and symptoms. History and examination are enough for the diagnosis of PVID, and investigation is of limited value. A fistulogram may be necessary to identify the part of the intestine involved preoperatively when an opening is observed within the umbilicus^{5,6}.

Diagnosis of patent urachus is mainly by history and physical examination and is confirmed surgically. In addition to clear discharge, patients may present with lower urinary tract symptoms. Ultrasonography is less effective in the case of patent urachus but more in urechal cyst¹. In this case, the ultrasonogram failed to diagnose any of the two components.

An umbilical polyp or adenoma is a round, reddish mass at the base of the umbilicus that comprises embryologic remnants of the vitellointestinal duct or, less commonly, the urachus. It is often brighter red and slightly larger than the umbilical granuloma. Sometimes umbilical polyps or adenomas are difficult to distinguish from umbilical granulomas that present as minimum discharge with moist, raw, radish-pink tissue arising from the base of the umbilicus. Umbilical

granuloma usually responds to cauterization, but polyp/adenoma does not respond. Following polyp/adenoma removal, histopathology should be performed to rule out embryological remnants^{9,10,11}. In the present case, the patient was initially diagnosed as having an umbilical granuloma and treated by chemical cauterization. But the disease was not cured as the umbilical adenoma does not respond to cauterization.

The mainstay of treatment for patent VID and patent urachus is laparotomy followed by excision of the embryonic remnants. This can be approached directly through the umbilicus (intraumbilical) or through an incision in the infraumbilical or supraumbilical crease^{1,12}. In this case, wedge excision of the vitellointestinal duct (VID) at the base followed by transverse anastomosis of the ileum was done. Due to its narrow base, the patent urachus was excised after ligation near to the urinary bladder.

CONCLUSION

The persistence of umbilical discharge may be due to congenital or acquired pathology. Acquired diseases usually respond well to conservative treatment. If there are no responses, one has to consider this may be due to persistence of the embryonic remnants (either urechus, vitellointestinal duct or both) and surgery is the mainstay of treatment.

REFERENCES

1. Cilley RE. Disorders of the Umbilicus. In: Coran AG, Adzick NS, Krummel TM, Laberge JM, Shamberger RC, Caldamone AA, editors. *Pediatric Surgery*. 7th ed. Philadelphia: Elsevier Saunders; 2012. p 961-72.
2. Snyder CL. Current management of umbilical abnormalities and related anomalies. *Semin Pediatr Surg* 2007; 16 (1): 41-9.
3. Abhyankara A, Lander AD. Umbilical disorders. *Surgery (Oxford)* 2004; 22 (9): 214-7.
4. Chawada. M, Ghavghave U. Patent urachus with patent vitellointestinal duct: a rare case. *Int J Recent Trends Sci Technol* 2013; 5 (3):137-8.
5. Rouma RS, Lakhoo K. 2011. Vitelline Duct Anomalies. In: Ameh EA, Bickler SW, Lakhoo K, Nwomeh BC, Poenaru D, editors. *Paediatric Surgery: A Comprehensive Text for Africa*. Washington: Global Help; 2011. p 389-92.
6. Ip JJK, Hui PKT, Lan L, Lam WWM, Chau MT. umbilical enteric fistula: a rare cause of neonatal umbilical mass. *Hong Kong J Radiol* 2012; 15:

- 192-6.
7. Sharma V. Umbilical discharge and its management in adults-rare presentation. IOSR-JDMS 2014; 13 (7): 45-8.
 8. Chughtai SA, Murad FM, Khan A, Malik AZ. Congenital umbilical fistula in an adult female. JUMDC 2011; 2 (1): 42-4.
 9. Assi AN, Kadem MK, Al Rubaee RJ, Atshan FG. Management of umbilical granuloma. TQMJ 2010; 4 (4): 82-7.
 10. Hossain AKMZ, Hasan GZ, Islam KMD. Therapeutic effect of common salt (table/ cooking salt) on umbilical granuloma in infants. Bangladesh J Child Health 2010; 34 (3): 99-102.
 11. Rakotomalala JH, Poenaru D, Mayforth RD. Disorders of the Umbilicus. In: Ameh EA, Bickler SW, Lakhoo K, Nwomeh BC, Poenaru D, editors. Paediatric Surgery: A Comprehensive Text for Africa. 1st ed. Washington: Global Help: 2011. P 352-357.
 12. Minkes RK, Megison SM. Disorders of the Umbilicus [Internet]. Emedicine.medscape.com. 2018 [cited 2019 December 13]. Available from: <https://emedicine.medscape.com/article/935618-overview>.